

# ANATOMICAL AND ULTRASONOGRAPHICAL STUDIES ON TENDONS AND DIGITAL CUSHIONS OF NORMAL PHALANGEAL REGION IN CAMELS (*Camelus dromedarius*)

A.M. Abu-Seida, A.M. Mostafa and A.R. Tolba\*

Department of Surgery, Anesthesiology & Radiology

\*Department of Anatomy & Embryology, Faculty of Veterinary Medicine, Cairo University, Cairo, Egypt

## ABSTRACT

In the present study, anatomical and ultrasonographical findings have been evaluated to be compared with abnormal digits in further studies. This study was carried out on 10 feet specimens of both fore and hind limbs from freshly slaughtered mature camels of both sexes and of different ages and body weights and digits of three apparently normal camels. Transverse and sagittal ultrasonographical examinations were carried out on all digits from fetlock joint to the nails using Toshiba ultrasound device connecting with 6-8 MHz linear transducer. Ten specimens of the digits were dissected anatomically to compare anatomical and ultrasonographical findings. All ultrasonographic and anatomic findings of common digital extensor tendon, superficial and deep digital flexor tendons, digital cushions and sole were described. In conclusion, ultrasonography is a highly impressive cross sectional diagnostic imaging in camel's digits.

**Key words:** Anatomy, camel, digital cushion, tendons, ultrasonography

The camel's foot resembles a tyre filled with fat instead of air (Blight *et al*, 1976). It is well designed to accommodate with the loose sandy soils of the desert (Wilson, 1984).

The foot pad of camels consisted of several layers including: the sole (cornified pad), common coverings, digital cushions and yellow bed (Hifney *et al*, 1988).

The foot affections in camels represented 42.5% of the total limb affections and the affections of the soft tissues of the foot represented 77.1% of the total foot affections (Zabady, 1999). Another study concluded that foot affections representing 46.9 % of the surgical affections causing lameness in camels (Mostafa, 1979). The soft tissues of the camel's foot are subjected to several affections (Zabady, 1999) as traumatic pododermatitis (Ibrahim, 1976), neoplasms (El-Seddawy, 1978 and Tagelddin and Omar, 1986), heel ulcer and separation of the cornified digital pad (Mostafa, 1979), sore feet, abscess, sole ulcer and elephant foot (Ramadan *et al*, 1986), burns (Gahlot *et al*, 1988), septic diffuse pododermatitis (Soliman *et al*, 1988), gangrene (Soliman *et al*, 1993), calcinosis circumscripta, edema of the foot, exuberant

granulation and herniation of digital cushions (Singh and Gahlot, 1997), idiopathic skin lesion (Shwartz and Dioli, 1998), and grain founder (Sharma and Sharma, 2006).

Although there are several studies on the osseous components of the camel's feet either normal feet (Mostafa *et al*, 1993) or diseased feet (Lotfia *et al*, 1996 and Ramadan *et al*, 1984), the studies on the soft tissues of the camel's feet are scarce.

Computed tomography (CT scan) as a recent diagnostic tool was used to describe the anatomical structures of the fore feet in normal camels (Badawy, 2011).

The aim of the present study is to describe the anatomical and ultrasonographical findings of the tendons and digital cushions of the normal camel's feet.

## Materials and Methods

The present study was divided into two parts including:

### I. Ultrasonographical study

This study was further divided into 2 parts:

---

SEND REPRINT REQUEST TO A.M. ABU-SEIDA [email: ashrafseida@yahoo.com](mailto:ashrafseida@yahoo.com)

### ***In vitro* study**

In this part of the study, ten apparently normal feet specimens of both limbs (Five fore limbs and 5 hind limbs) were obtained from recently slaughtered mature camels which were of both sexes and of different ages and body weights. Each foot was cleaned, clipped and shaved at the dorsal and planter aspects of the phalngeal region. After using the ultrasound coupling gel, the area from the fetlock to the nails was scanned in both sagittal and transverse planes in each digit. This area was scanned on dorsal, planter and solar aspects using Toshiba ultrasound device connecting to 6-8 MHz linear and transducer. The scans were fixed and printed.

### ***In vivo* study**

In this part of the study, the four feet of 3 clinically normal mature camels were examined ultrasonographically by the same method used *in vitro* study.

The camels were tranquilized by using Xylazine HCl 2% solution at a dose of 0.1 mg/kg BW given intravenously. The camels were examined at both sternal and lateral recumbency using the same ultrasound device.

## **II. Anatomical study**

After ultrasonographic examination of 10 camels' feet specimens, these were immersed in a mixture of formalin (10%) and phenol (5%) for normal anatomical dissection.

## **Results**

### **I. Ultrasonographical findings**

Common digital extensor tendon appears on the sagittal scan at the dorsal aspect of fetlock joint as a hyperechoic band of 9-15 mm width then bifurcates into medial and lateral hyperechoic branches of 8-10 mm width (Fig 1a). At the level of both fetlock and pastern joints the tendons flattens and becomes thinner than above and below these joints (Fig 1b).

Superficial digital flexor tendon appears as hyperechoic thick band of 15-20 mm width and thickness which splits just below the fetlock joint to pass the hyperechoic deep digital flexor tendon.

Deep digital flexor tendon appears as hyperechoic band in sagittal scan and appears as hyperechoic oval structure surrounded by anechoic synovial fluid and hyperechoic tendon sheath in transverse scan (Fig 2a). The tendon has 2 hyperechoic enlargements at the fetlock joint and under the second phalanx.

On sagittal scan of the solar aspect, the middle digital cushion is the largest one appears as fish-like high echogenic homogenous structure which has head, body and tail and occupies most of the foot (Fig 2b) while the abaxial and axial digital cushions are seen as thin echogenic bands reflected over the middle digital cushion and widens at toes and heels levels.

On transverse scan of the solar aspect, digital cushions appear as 3 high echogenic homogenous structures which are surrounded with common hyperechoic capsule. The middle digital cushion appears as an oval or rounded echogenic structure of 30-40 mm in thickness and 30-50 mm in width in fore feet and 25-40 mm in thickness and 20-35 mm in width in hind feet. It is surrounded by 2 crescentic echogenic structures representing the axial and abaxial digital cushions (Fig 3). The axial digital cushion is thicker than the abaxial one.

At the level of the interdigital notch, the transverse scan of the solar aspect shows 2 crescentic echogenic structures representing the axial digital cushions of both claws which are separated by anechoic interdigital septum and 2 rounded echogenic structures representing the middle digital cushions of both claws (Fig 4). The digital cushions of the fore feet are larger than that of the hind feet.

The sole consisted of hyperechoic thin keratinised layer and thick anechoic layer (Fig 3). The thickness of the sole was 9-12 mm at the cranial part of the foot and decreased gradually backward to be 6-7 mm at the heel level.

### **II. Anatomical findings**

The common digital extensor tendon is bifurcated below the level of fetlock joint into medial and lateral tendons (Fig 5). The medial one is more slender than the lateral and become the proper extensor of the third digit. Common digital extensor runs over the fetlock joint where it is flattened (with a 10-12 mm width) then fuses with the joint capsule. A part of its insertion is on the proximal dorsal aspect of the first phalanx, while the other part continues to insert on the distal aspect of the first phalanx and the proximal surface of the second phalanx. The continuation of the common digital extensor tendon bifurcated over the fetlock joint, where it is held in position by elastic fibres. It attaches to the dorsal aspect of the middle phalanx of each digit. They do not reach third phalanx.

Superficial digital flexor tendon (Fig 6) bifurcates below the middle of the metacarpus with

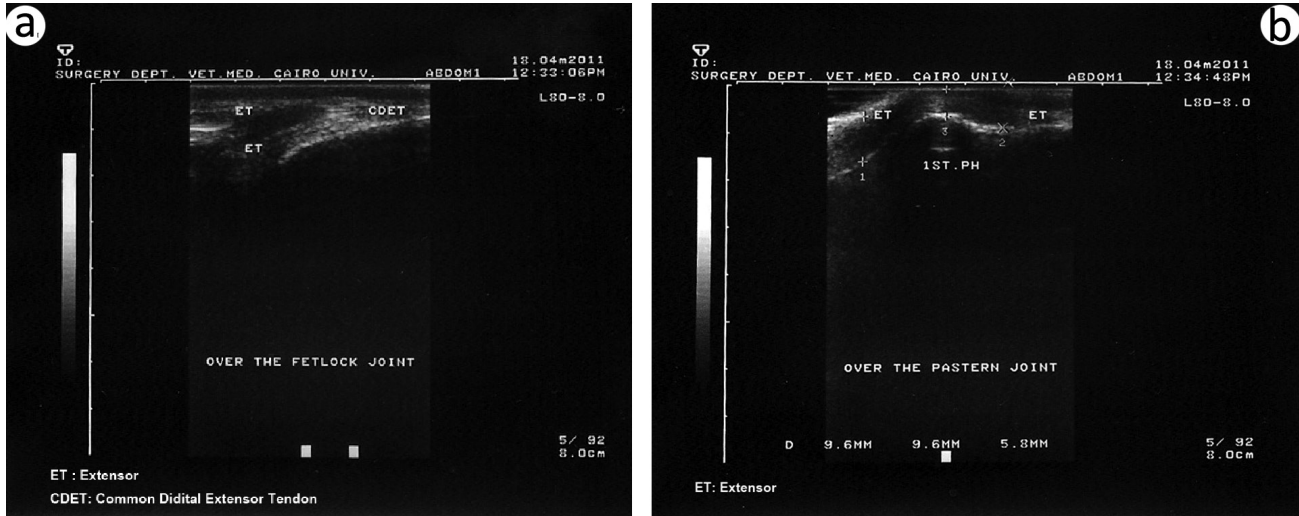


Fig 1. (a) sagittal ultrasonogram just below the fetlock joint showing the bifurcation of hyperchoic common digital extensor tendon. (b) Sagittal ultrasonogram at the dorsal aspect of the pastern joint showing the stretching of the extensor tendon.

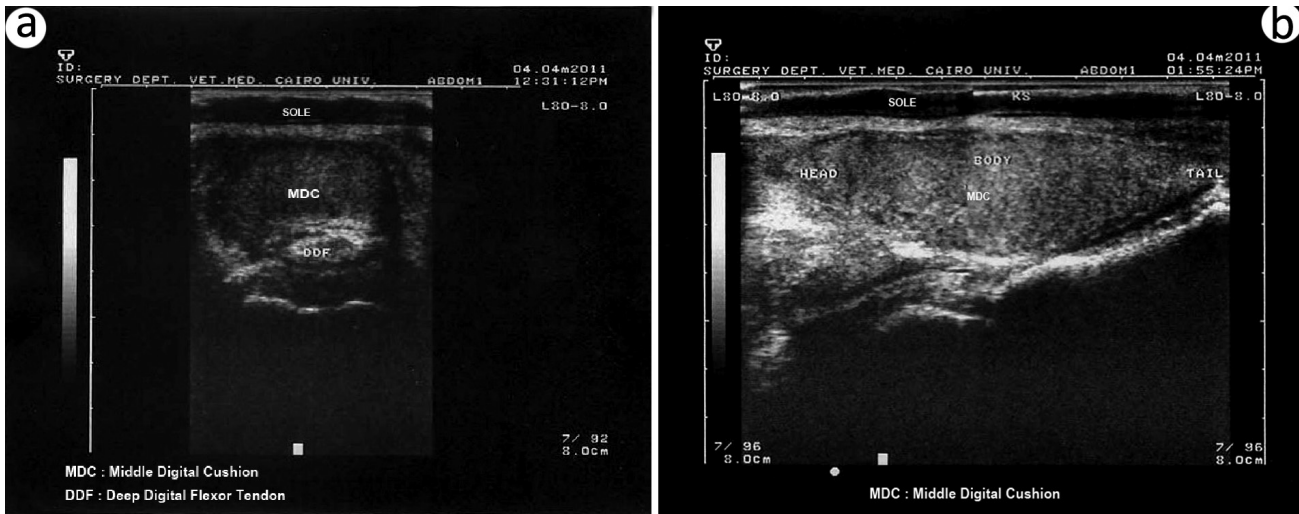


Fig 2. (a) Transverse ultrasonogram at the middle third of the solar aspect of the claw showing high echogenic oval middle digital cushion and oval hyperchoic fibrocartilagenous enlargement of the deep digital flexor tendon. (b) Sagittal ultrasonogram of the middle digital cushion showing high echogenic fish-like structure surrounded with hyperchoic capsule.

20-22 mm width. Superficial digital flexor tendon accompanies the deep digital flexor tendon over the fetlock region. Distal to this joint, it splits to allow the passage of the deep digital flexor tendon (Fig 7). It passes between the proximal phalanx and deep flexor tendon. It inserts on the proximal palmar aspects of the middle phalanx.

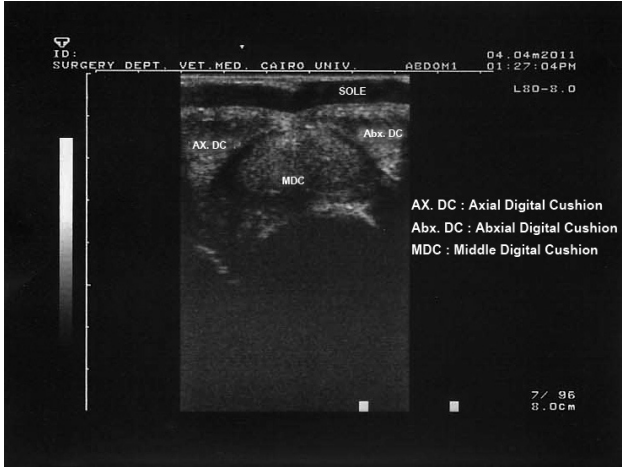Deep digital flexor tendon (Fig 6, 7) splits in the distal fourth metacarpus. It pierces the bifurcation of the superficial flexor tendon. It passes over the palmar surface of the second phalanx, at which the borders of the tendon at this region is flattened and supported by fibrocatilage then continues as sheets which attach to the sides of bone. This upper fibrocartilagenous

enlargement (Fig 6) is 7-9 mm in width and 45-55 mm in length.

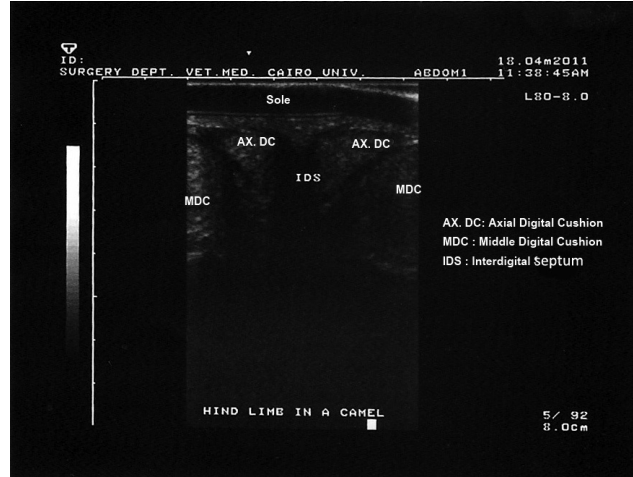
Deep digital flexor tendon runs till the coffin joint, where it is enlarged and reinforced by fibrocartilage (the lower fibrocartilagenous enlargement (Fig 6, 7). The width and length of this lower enlargement are 13-15 mm and 33-37 mm, respectively. Finally it inserts on the flexor surface of the third phalanx.

The digital cushions (Fig 7, 8) are consisted of 3 cushions including axial, abaxial and fish-like middle digital cushions. The middle cushion has 10 cm length, 4 cm width and 2.5 cm thickness. It consists of head, body and tail. The axial digital cushion is larger

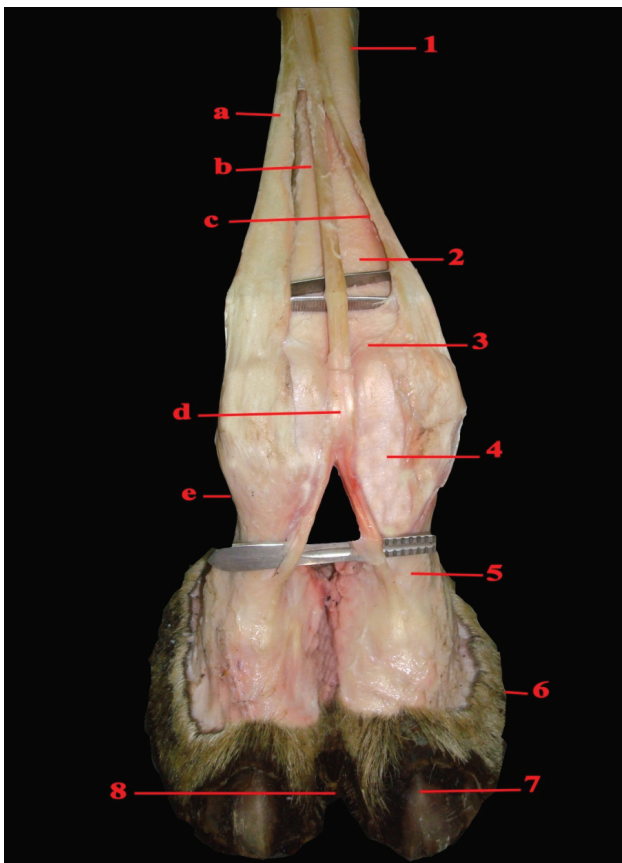




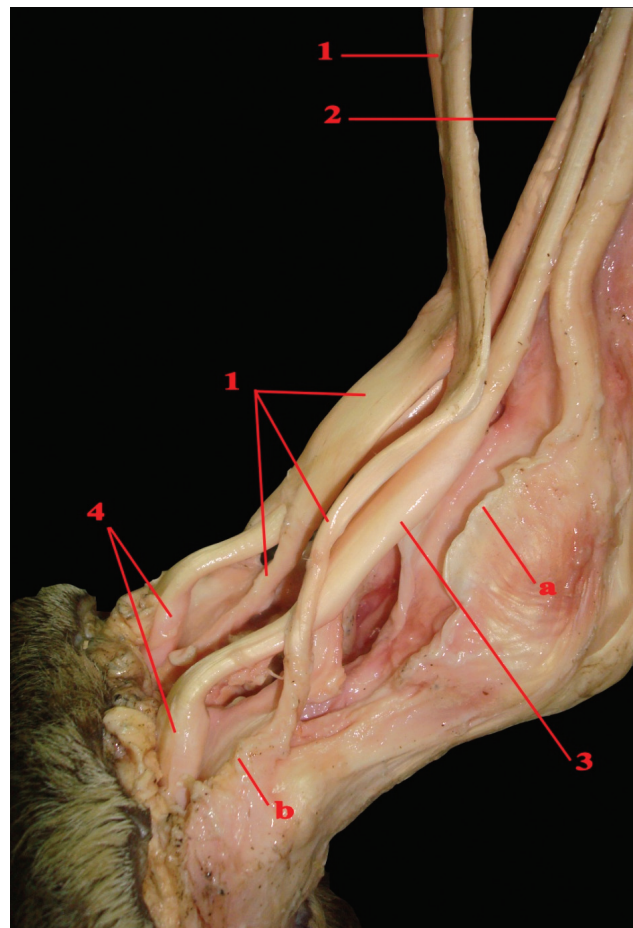
**Fig 3.** Transverse ultrasonogram at the middle third of the solar aspect of one claw showing, hyperechoic cornified sole, anechoic epidermal layer and high echogenic digital cushions. Notice the crescentic appearance of the axial and abaxial digital cushions and the oval appearance of the middle one.



**Fig 4.** Transverse ultrasonogram at the level of interdigital septum showing two crescentic axial digital cushions, two oval middle cushions of both claws and anechoic interdigital septum.



**Fig 5.** Dissected dorsal view of the camel's phalangeal region  
**1.** Metacarpal bone, **2.** Divided metacarpal bone, **3.** Fetlock joint, **4.** Proximal phalanx, **5.** Pastern joint, **6.** Sole, **7.** Nail, **8.** Interdigital notch.  
**a.** Tendon of *M. extensor digitorum lateralis*, **b** & **c.** Tendon of *M. extensor communi*, **d.** Common digital extensor tendon, **e.** Proper tendon of the digit.



**Fig 6.** Dissected lateropalmer view of the camel's phalangeal region: **1.** Superficial digital flexor tendon which splitted to pass **2.**, **2.** Deep digital flexor tendon, **3.** Upper fibrocartilagenous enlargement, **4.** Lower fibrocartilagenous enlargement.  
**a.** Proximal scutum, **b.** distal scutum

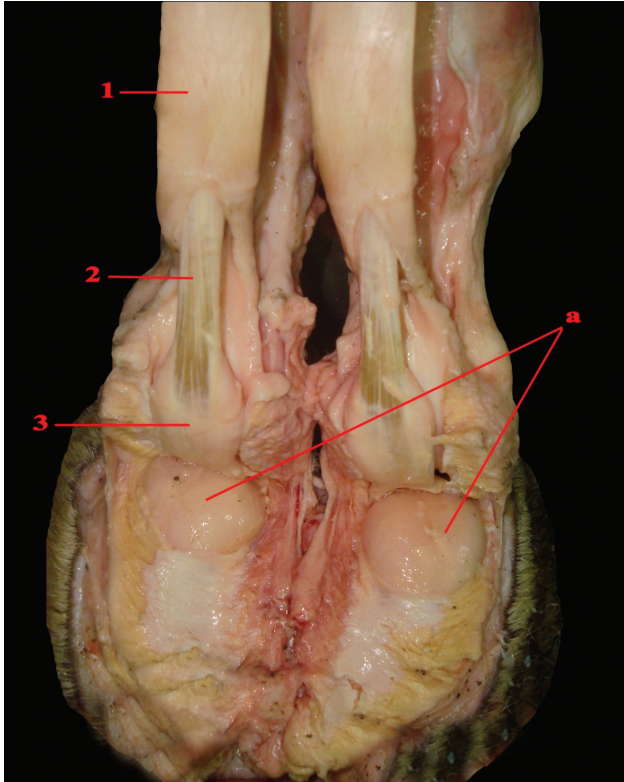


Fig 7. Dissected Planter view of the camel's phalangeal region: 1. Superficial digital flexor tendon which splitted to pass 2, 2. Deep digital flexor tendon, 3. Lower fibrocartilagenous enlargement, a. Middle digital cushion

than the abaxial one (Fig 8b) and the digital cushions of hind feet are smaller than that of fore feet. The digital cushions are underlying the 2 distal phalanges. Each digital cushion consisted of soft adipose tissue encapsulated by collagen connective tissue.

### Discussion

Many studies were carried out on the bones and joints of the camel's foot but studies on soft tissues are scarce (Dehgheni *et al*, 2011 and Nourinezhad *et al*, 2011). The previous studies concluded that bones and articular affections of the camel's feet are rare while the affections of the soft tissues of the foot are common causing lameness. The large flat foot with its flexible sole adopts camels to progress over loose sand. Anticoncussion mechanism along the different joints of the camel's limbs is well supported and more established in comparison with that in horses. This explains the rarity of bone diseases along the camel's limbs (Mostafa, 1979).

In addition, pathological changes of the interphalangeal joints occur rarely in camels compared to the other domestic animals due to wide joints, capsules, limited physiological movement and the presence of strong tendons and ligaments, digital cushions and foot pad (Lotfia *et al*, 1996).

Pododermatitis is the most prevalent affection in camel because of the comparatively soft nature

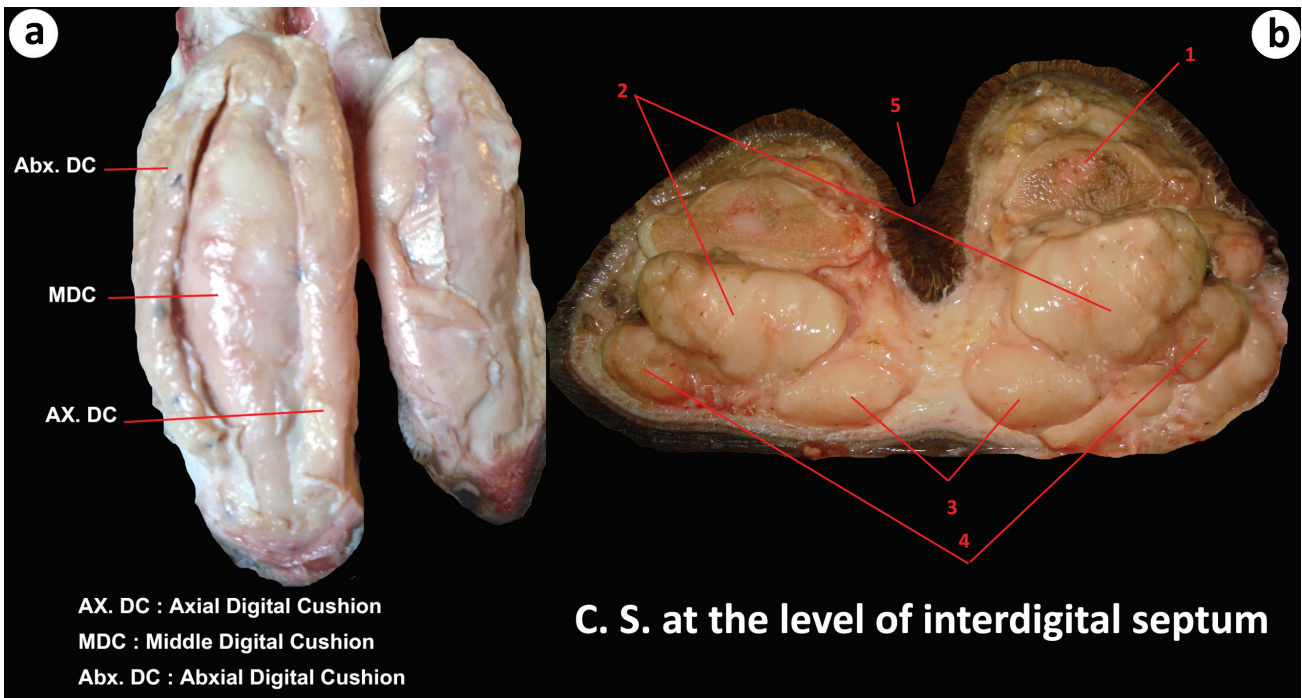


Fig 8. (a) Dissected solar view of camel's foot showing the three digital cushions. (b) Cross section at the level of interdigital septum showing the digital cushions. 1. Middle phalanx, 2. Middle digital cushion, 3. Axial digital cushion, 4. Abaxial digital cushion, 5. Interdigital septum.



of the foot pad which is easily punctured by sharp objects (Mostafa, 1979 and Zabady, 1999). These sharp objects produce severe inflammation, suppuration and great thickening of the whole foot making the physical examination of the foot too difficult. Therefore the using of ultrasonographical examination will be beneficial in these conditions.

Although ultrasonography has been used since long time in large animals practice, its use in camels is still limited. Ultrasonography of the camel's foot is a useful diagnostic tool due to the comparatively soft sole. In contrast, other study concluded that soft tissues of the equine foot are difficult to be evaluated by ultrasonography due to its hard sole (Denoix *et al*, 2005).

Comparing the 4 diagnostic imaging techniques i.e. radiography, ultrasonography, computed tomography scan and magnetic resonance imaging; ultrasonography is the most useful and available tool for cross sectional imaging on digits (Raji *et al*, 2008 and Badawy, 2011). Although computed tomography scan is an excellent modern diagnostic imaging (Badawy, 2011), its use in camels is difficult as it is so expensive and the animal needs general anaesthesia for examination.

Ultrasonographic examination of the solar aspect of the camel's foot was more impressive than the examination of dorsal aspect due to the presence of the phalangeal bones dorsally. Similar finding was recorded in CT imaging in camel's foot (Badawy, 2011).

The common digital extensor tendon appeared as thick hyperechoic band which divided into 2 branches. It overstretched over the fetlock; pastern and coffin joints due to the bony prominences of the phalanges therefore it was appeared thin at these areas. This is in agreement with recent study (Nourinezhad *et al*, 2011).

The deep digital flexor tendon also appeared as hyperechoic band which had 2 hyperechoic flattened fibrocartilaginous areas. The lower enlargement act as a protector of digital cushions from the phalangeal bones. Some authors named the lower fibrocartilaginous enlargement, distal cartilaginous sesamoid (Smuts and Bezuidenhout, 1989).

Digital cushions composed of elastic adipose tissue which separates the bones from the horny foot pad which prevent undue concussion on hard ground. These cushions appeared as high echogenic structures due to its content of adipose tissue and surrounded by hyperechoic collagenous capsule.

The axial digital cushions are larger than the abaxial ones to support the interdigital septum. The digital cushions of the fore feet were larger than that of the hind feet because the fore limbs carry most of the camel weight. Similar findings were reported in previous studies (Mostafa, 1979; Zabady, 1999 and Badawy, 2011).

The interdigital septum appeared as anechoic structure due to its high vascularity. Similar explanation was mentioned on another study (Badawy, 2011).

The sole appeared ultrasonographically as thin keratinised hyperechoic sole pad and thick anechoic epidermal layer. In addition, its thickness decreased gradually backward. These findings were in agreement with the results of another study (Zabady, 1999).

By comparing the anatomical and ultrasonographical findings of this study, it was concluded that ultrasonography is a highly impressive cross sectional diagnostic imaging in the camel's digits.

## References

- Badawy AM (2011). Computed tomographic anatomy of the fore foot in one-humped camel (*Camelus dromedarius*). *Global Veterinaria* 6(4):417-423.
- Blight J, Cloudsley J and MacDonald A (1976). *Environmental Physiology of Farm Animals*. Textbook 1st. ed., Blackwell Scientific Publications, Oxford, U.K.
- Dehgheni S, Kohkilaye HM and Sazmad A (2011). Digital angiography of the camel foot. *Journal of Camel Practice and Research* 18(1):119-121.
- Denoix JM, Crevier N, Roger B and Lebas JF (2005). Magnetic resonance imaging of the equine feet. *Veterinary Radiology and Ultrasound* 6:405-411.
- El-Seddawy FD (1978). Studies on unsoundness blemish and vices in camels (*Camelus dromedarius*). M.V.Sc. Thesis, Fac. Vet. Med., Zagazig University-Egypt.
- Gahlot T, Chouhan D and Choudhary R (1988). Management of surgical diseases in camel. *Indian Journal of Veterinary Surgery* 3(2):100-102.
- Hifney A, Amin M and Karkoukra A (1988). Anatomical studies of foot pad of the camels. *Alex. Journal of Veterinary Science* 4(1):1-7.
- Ibrahim AK (1976). Studies on the surgical affections of the camel. M.V.Sc. Thesis, Fac. Vet. Med., Zagazig University-Egypt.
- Lotfia SF, Hegazy AA, Sheta EM and Waly Y (1996). An approach to the phalangeal region affections in camel (*Camelus dromedarius*). *Veterinary Medical Journal Giza* 44(2):259-272.
- Moustafa MA (1979). Surgical affections causing lameness in camels. M.V.Sc. thesis, Faculty of Veterinary Medicine, Zagazig University.

- Moustafa MB, Farag KA and Ragab GA (1993). Arthrography of the interphalangeal joints in the camel. *Camel Newsletter* 1:20-28.
- Nourinezhad J, Mazaheri Y and Mohabady UK (2011). Gross anatomy of the ligaments of fetlock joint in dromedary camel. *Journal of Camel Practice and Research* 18(2): 197-202.
- Raji AR, Sardari K and Mohammadi HR (2008). Normal cross sectional anatomy of bovine digits: comparison between computed tomography and limb anatomy. *Anatomia Histologia Embriologia Journal of Veterinary Medicine* 37:188-193.
- Ramadan RO, Etayeb FM and Ismail OE (1984). Foot lesions in camels. *Equine Practice* 6(5):31-37.
- Ramadan RO, Kock RA and Higgins AJ (1986). Observations on the diagnosis and treatment of surgical conditions in the camel. *British Veterinary Journal* 142:75-89.
- Schwartz H and Dioli M (1998). *The one-humped camel in Eastern Africa. A pictorial guide to diseases, health care and management.* Verlag Josef Margraf, Scientific books, Germany.
- Sharma NK and Sharma S (2006). Grain founder in a male camel (*Camelus dromedarius*). *Journal of Veterinary Science* 7(1):91-92.
- Singh G and Gahlot TK (1997). Foot disorders in camels. *Journal of Camel Practice and Research* 4(2):145-154.
- Smuts MM and Bezuidenhout AJ (1989). *Anatomy of The Dromedary, 1st Ed., Clarendon press, Oxford.* pp 87-90.
- Soliman I, Moustafa Mand Mezyein A (1988). Angiographic alterations of some foot affections in camels. *Proc. 3rd Cong., Fac. Vet. Med., Assuit Univ. Egypt.* pp 13-24.
- Soliman I, Othman GM and Kamel A (1993). Amputation of the digit in the camel. *Journal of Egyptian Veterinary Medical Association* 43:131-137.
- Tageldin M and Omar FA (1986). A note on squamous cell carcinoma in a camel. *Indian Veterinary Journal* 63(7):594-595.
- Wilson RT (1984). *The Camel. 1st Ed., Burnt Mill, Harlow, Essex, U.K.*
- Zabady MK (1999). *Studies on some limb affections in camels (Camelus dromedarius).* Ph.D. thesis, Cairo University.